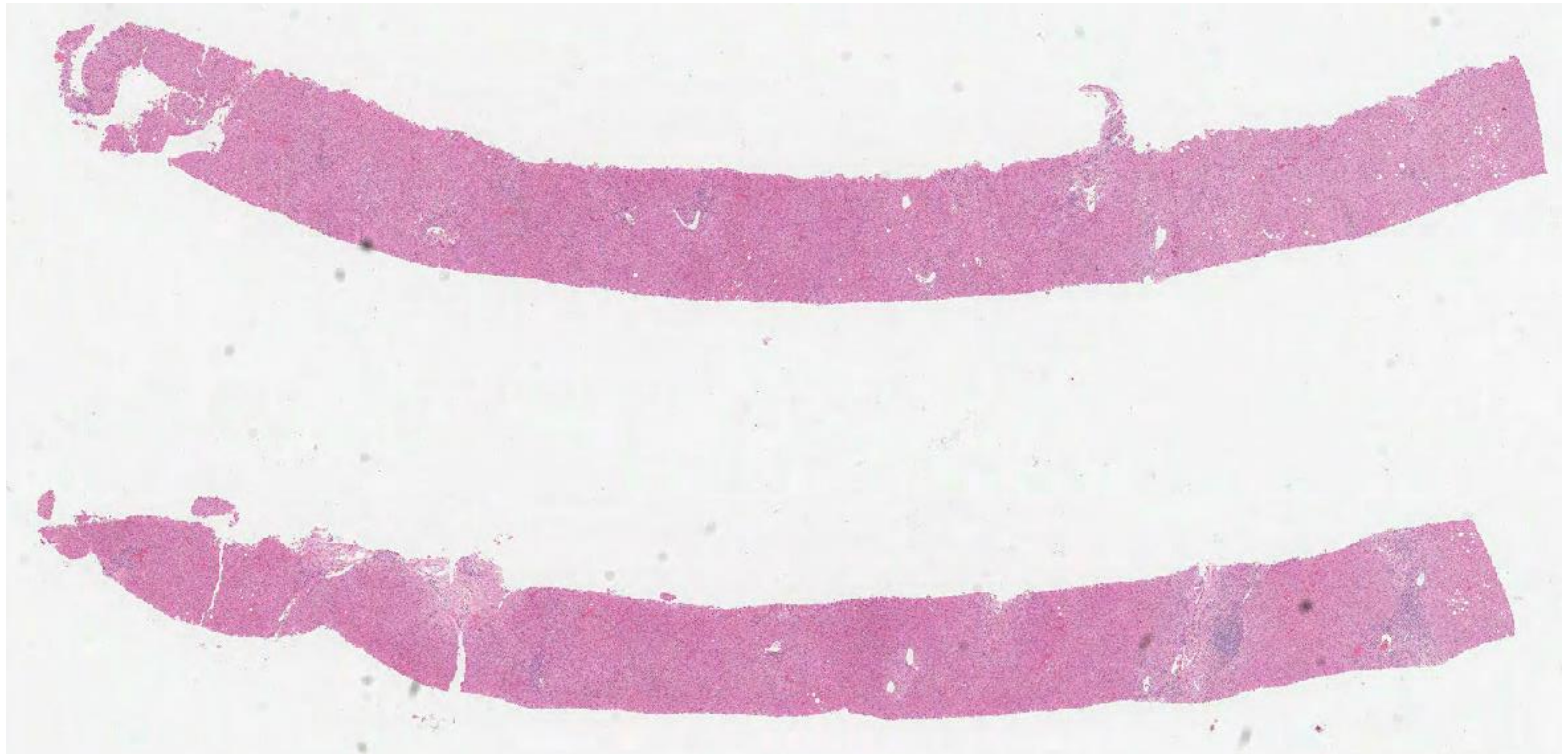


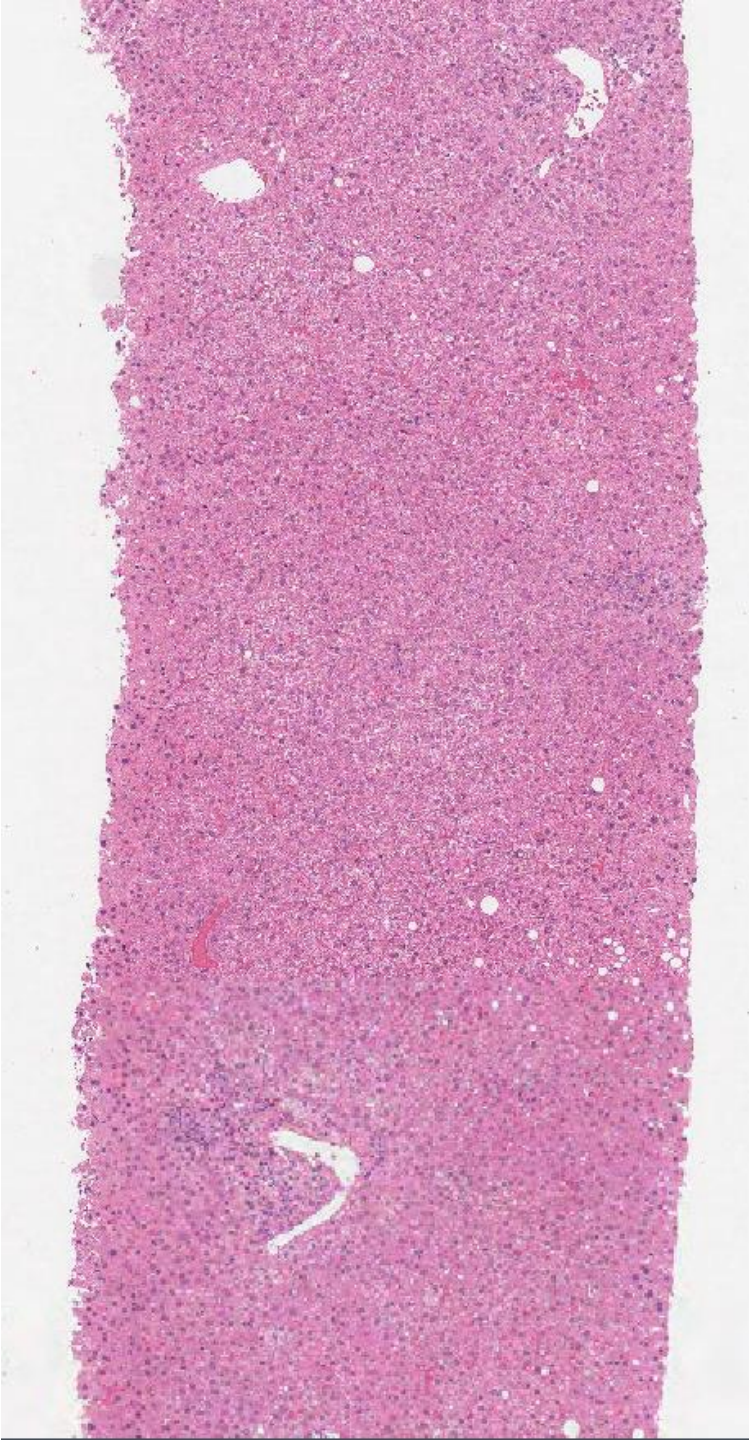
Case LS2 75M

Mixed picture of abnormal LFTs - on Sodium Valproate, risk factors for NAFLD (obesity, HBP and high cholesterol), also previous biliary issues with open cholecystectomy and CBD clearance for stones.

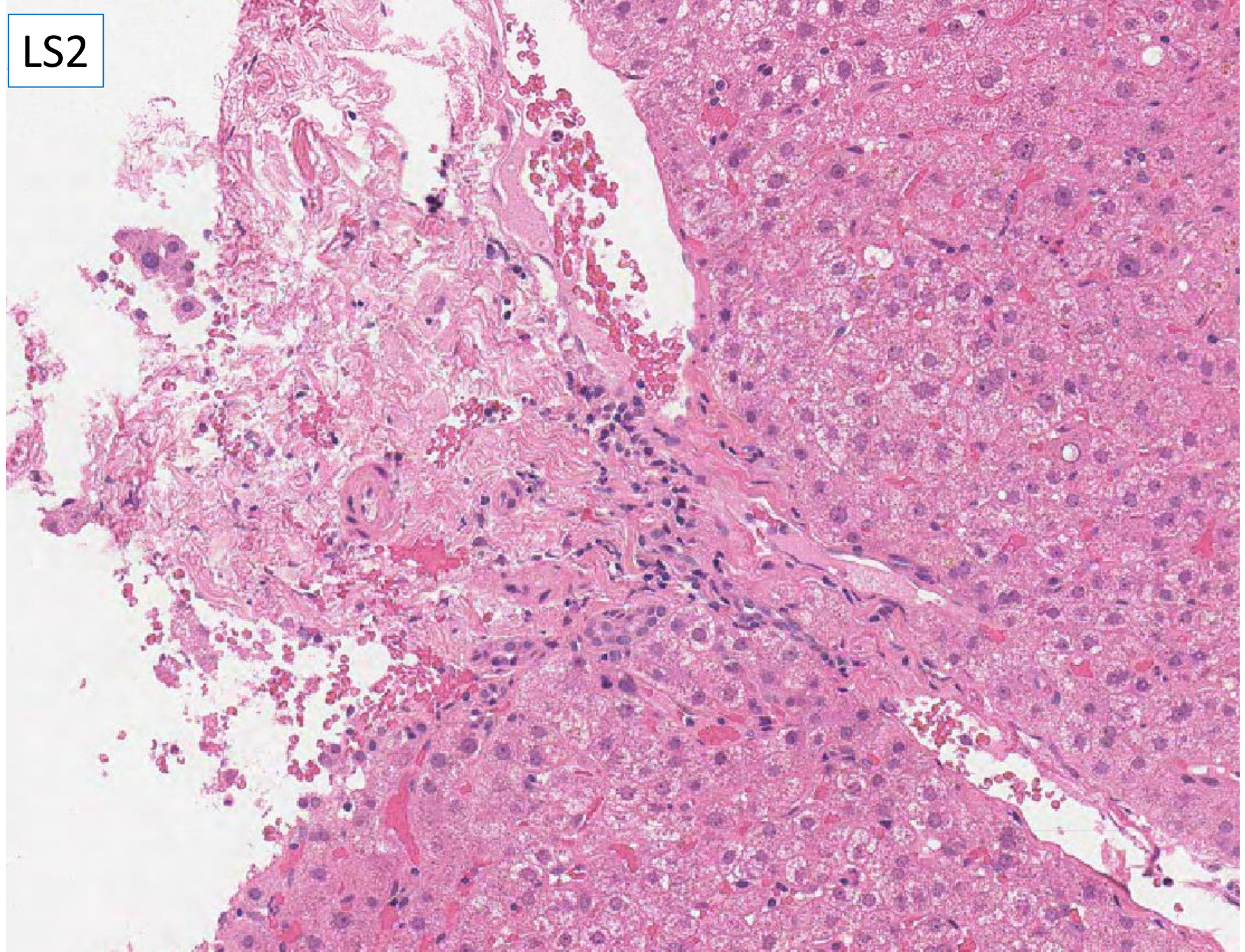
Surgical team working up for incisional hernia repair - but noted ongoing abnormal LFTs.
MRCP ?? PSC. Biopsy - ? NASH/?DILI or PSC.
Also HVG, rhodanine



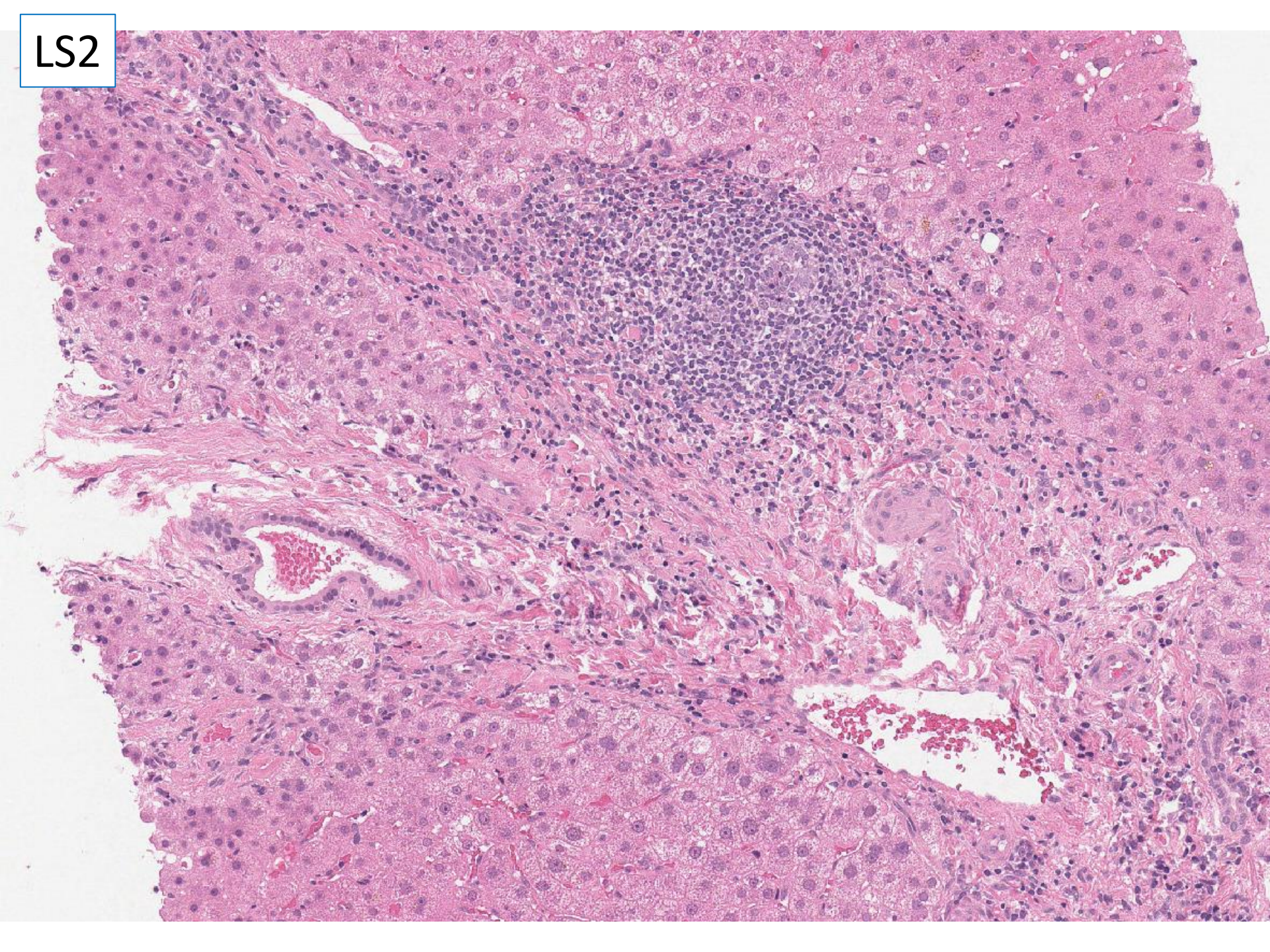
LS2



LS2

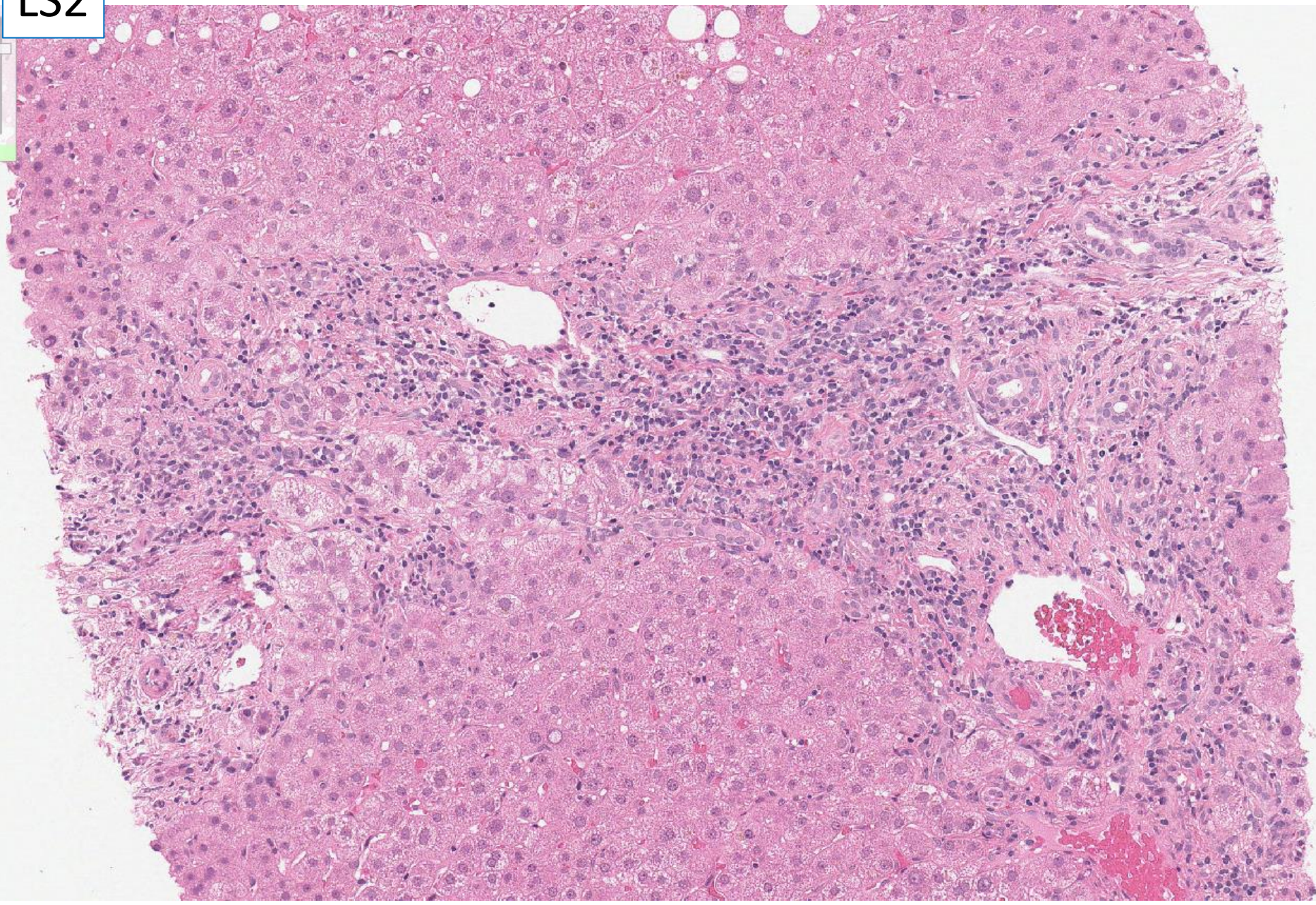


LS2

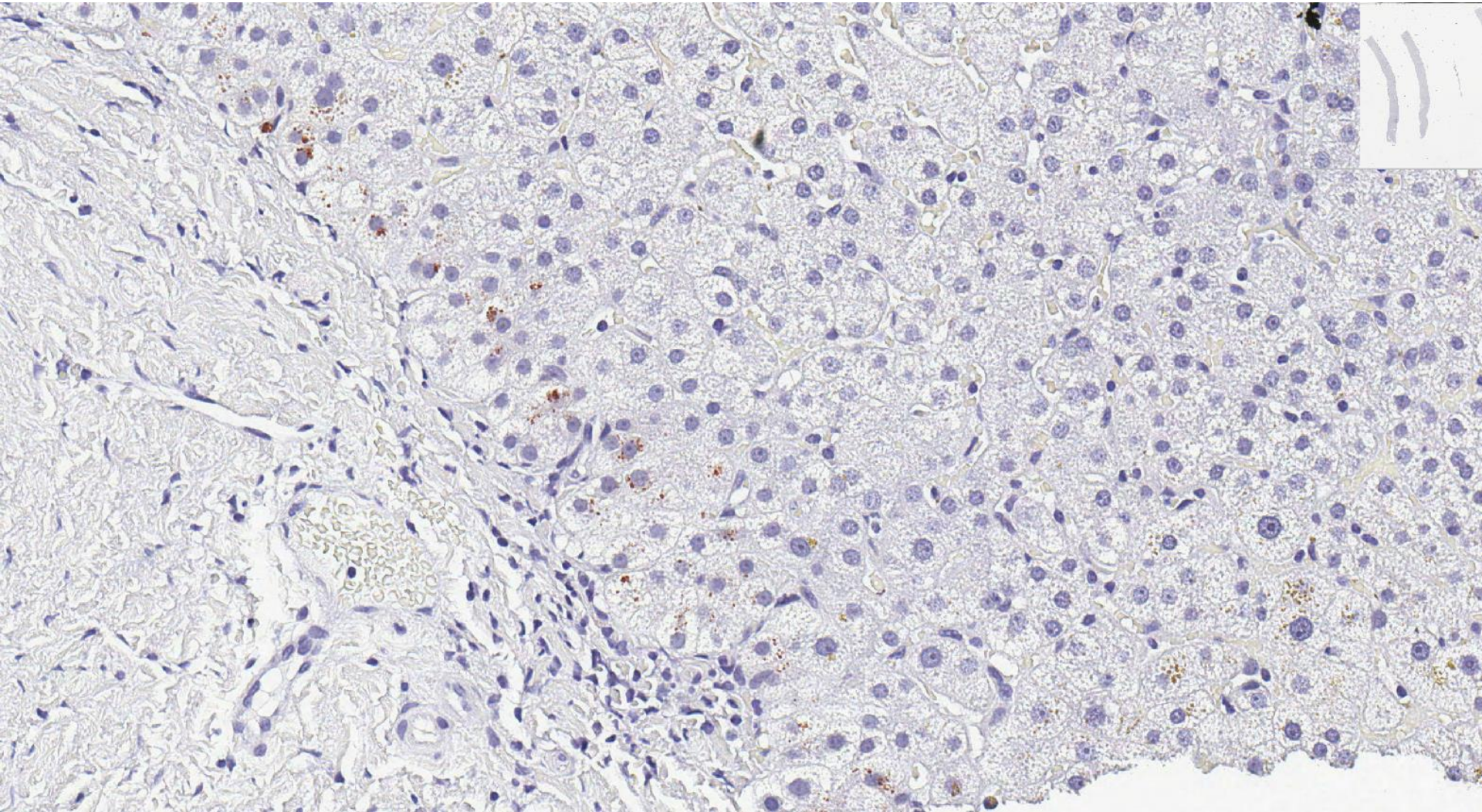


LS2

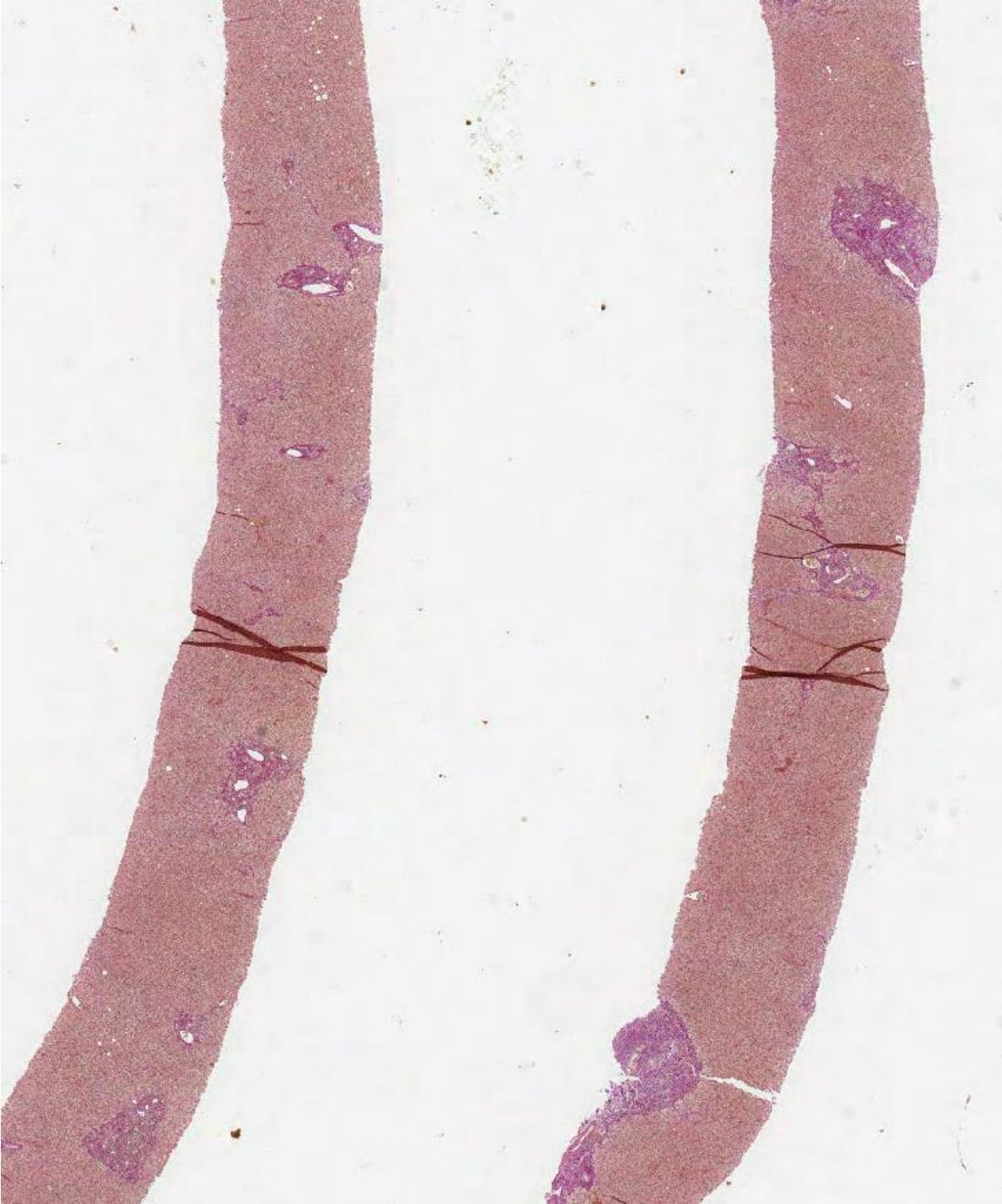2X



LS2 rhodanine



LS2



Case LS2 75M

Mixed picture of abnormal LFTs - on Sodium Valproate, risk factors for NAFLD (obesity, HBP and high cholesterol), also previous biliary issues with open cholecystectomy and CBD clearance for stones.

Surgical team working up for incisional hernia repair - but noted ongoing abnormal LFTs.

MRCP ?? PSC. Biopsy - ? NASH/?DILI or PSC.

Also HVG, rhodanine

A	Fatty liver disease
B	Drug induced liver disease
C	Biliary disease (PSC or large duct obstruction/stone)
D	Chronic hepatitis
E	cirrhosis